

PATIENT

Tank Domurat

SPECIES

Canine

BREED

Doberman

SEX

Male Neutered

AGE

9 years

WEIGHT

90 lbs

INTERPRETED BY

Maggie Machen Lamy,
DVM, DACVIM
(Cardiology)

IMAGING PERFORMED BY

PRESENTING CLINICAL SIGNS

History: Doing well. Repeated holter after starting Sotalol on 8/30/22. Owner has been restricting activity level. Currently medications as of 8/30/2022 1) Sotalol 80mg 1/2 tab twice a day 2) Taurine 1000mg twice a day 3) Fish oils

Pertinent echo findings (MML 8/23/2022): borderline FS, trace MR/TR/AI; no LA/LVE
Pertinent holter findings (MML 8/30/2022): 1407 VPCs, 18 couplets, 6 runs

HOLTER MONITOR FINDINGS AND RHYTHM ASSESSMENT

Time analyzed	22:45h
Mean heart rate	55bpm
Maximum heart rate	196bpm
Minimum heart rate	28bpm
VPCs	534; 1 couplet
APCs	0

Interpretation: Underlying normal sinus rhythm with appropriate rate variation. Dramatic improvement in VPC count overall; primarily singles with one couplet. No VT noted. Periods of trigeminy noted.

Rhythm diagnosis: Sinus rhythm with apparently well controlled ventricular arrhythmias.

RECOMMENDATIONS

Sinus rhythm with improved ventricular arrhythmias. The numeric count is decreased by 60+%, and of greater relevance no persistent VT is seen. A single couplet is noted; however, R on T phenomenon is not present. No additional issues are identified.

This is considered a positive response to the medication, with reasonable control. Continued sotalol is recommended as prescribed. It is important to note that even in human trials, anti-arrhythmics have not been shown to prevent sudden death in these patients, and high risk will unfortunately persist. Activity/stress restriction is advised lifelong while maintaining QOL.

Monitor for any significant lethargy or collapse in the patient while going forward.

Continued fish oil supplementation is recommended for dogs with arrhythmias (1000mg of omega 3 and 6 once to twice daily).

Plan: Continue Sotalol as prescribed.

A ECG/holter monitor/BP/echocardiogram is recommended in 6 months, sooner if episodes of collapse occur.

HOSPITAL NAME

Mass Veterinary Services

REFERRING VET

Dr. Masloski

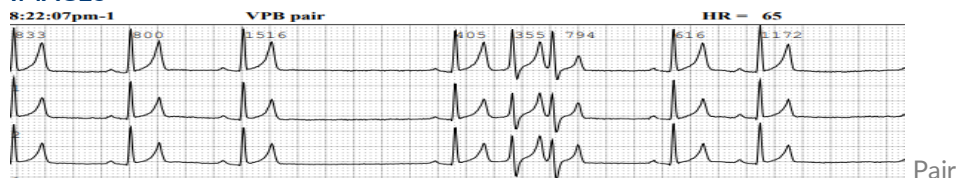
INVOICE

26866

DATE

10/12/22

IMAGES





PATIENT

Tank Domurat

SPECIES

Canine

BREED

Doberman

SEX

Male Neutered

AGE

9 years

WEIGHT

90 lbs

INTERPRETED BY

Maggie Machen Lamy,
DVM, DACVIM
(Cardiology)

IMAGING PERFORMED BY

HOSPITAL NAME

Mass Veterinary
Services

REFERRING VET

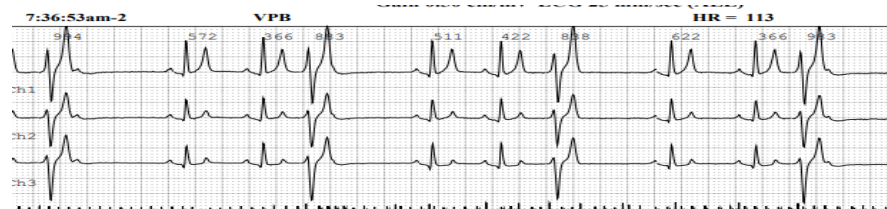
Dr. Masloski

INVOICE

26866

DATE

10/12/22



Trigeminy

The information and recommendations provided are based on the images presented by the referring veterinarian. No evaluation can be communicated regarding pathology that was not visible in the image/video clips provided.

Thank you for this referral. If the clinical or image interpretation does not parallel your findings or if I can be of any further assistance please contact me.

Maggie Machen Lamy, DVM
Diplomate of the American College of Veterinary Internal Medicine (Cardiology)
info@sonopath.com